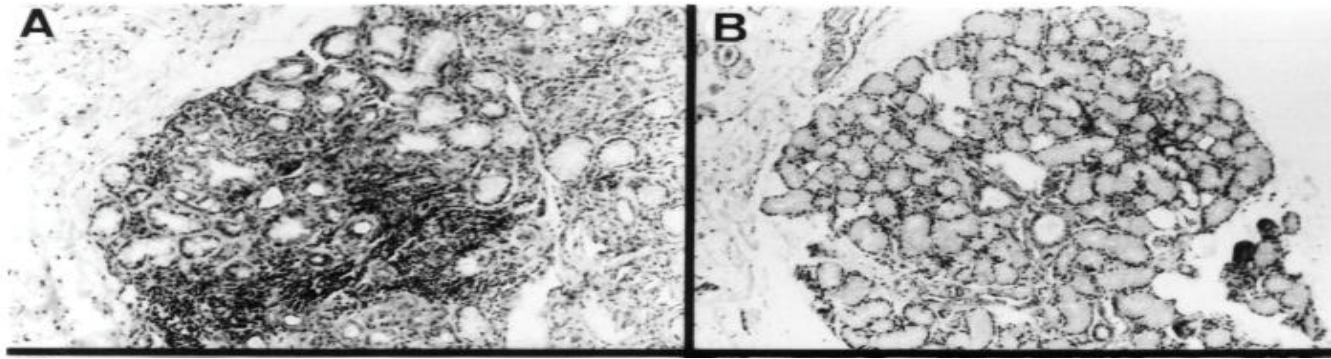


In Sjogren's syndrome,
many acini and ducts are spared



Sjogren's

Normal